Parenchyma saving resections- fictions or facts? (Colorectal liver metastasis)

Bjørn Edwin, professor, MD, PhD
Section manager, Clinical Research
The Interventional Center and HPB-Department
Oslo University Hospital, Rikshospitalet
Oslo, Norway

The Intervention Centre

Oslo University Hospital

Total laparoscopic experience (1998-Aug.2014) N =643

- **Lap. liver resections**
  - 643 pat., 713 procedures
  - Re-resections: 101 procedures (31 after open surgery and 70 procedures after laparoscopy)
  - approx. 60% colorectal metastases
  - 35 HCC patients

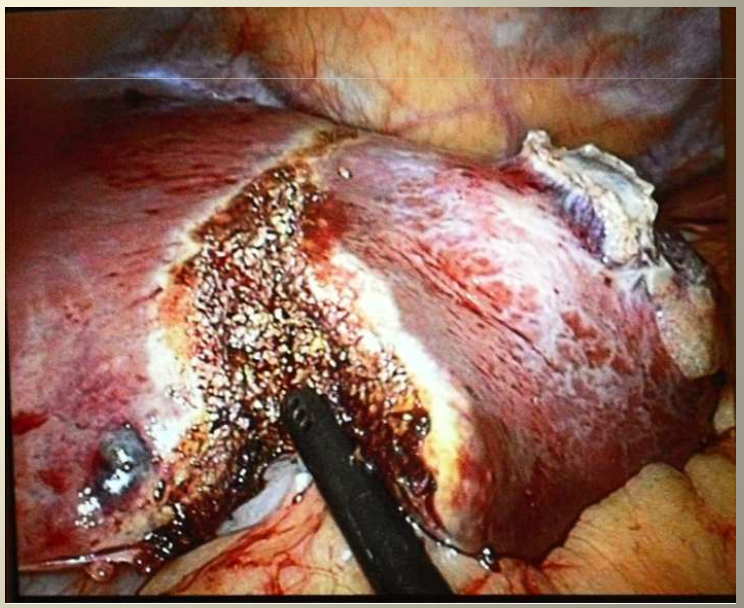

What is parenchyma/parenchymal sparing/saving resection/technique (PST)

- Definition:
  - A technique sparsely described in the literature
  - A resection that removes the metastasis without compromising cancer-related outcome, sparing as much healthy parenchyma as possible
  - *What is gold standard in 2014 – formal or parenchyma sparing? Differs from surgeon, country, culture , disease*

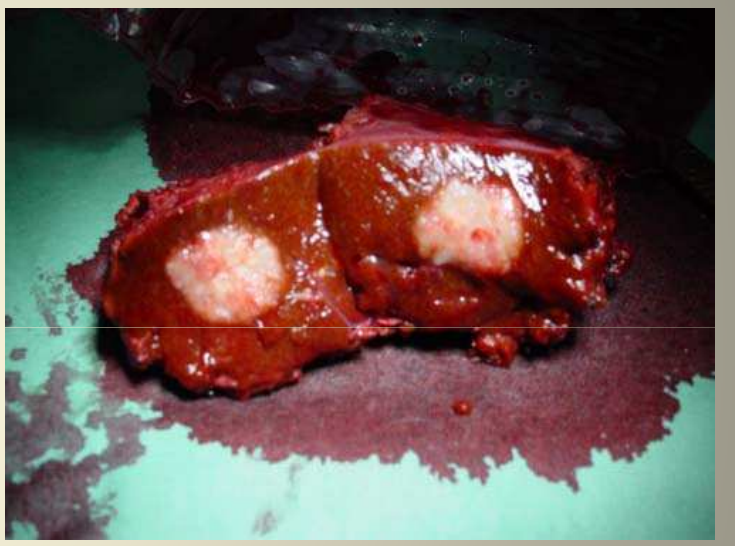

”Minimal invasiv surgery, Re-generation Parenchyma sparing technique was described very early”



Zevs eagle eating a part of Prometheus liver every day but during the night it re-generated

(Greek Mythology)

Painter Pieter Paul Rubens



530 BC

PST

- Resection
  - Reduce numbers of segments e.g. seg. 6/7 instead of formal right side hemihepatectomy
- Atypical, local, wedge resection

- What about local ablations:
  - Cryo, RF, Nanoknife, Microwave, HIFU etc.

Why

Parenchyma saving resections?

Short introduction:

Treatment of liver metastasis from colorectal cancer

Resectability

- 10-30% of all pat.with liver metastasis from colorectal cancer is potential candidates for curative liver resections[1,2]

[1] McArter MD/ Fong Y. Sem Surg Oncol 2000; 19: 177-188
[2] Scheele J. Br J Surg 1993; 80: 274-276

Survival without operation

metastasis from colorectal cancer

median survival of

10-13 months

Chemotherapy

(overall survival)

	FOLFIRI/FOLFOX	FOLFOX/FOLFIRI
Median (month)	**20.4** [16.7-24.9]	**21.5** [17.3-24.8]
Events/patients	65/109	67/111
Median followup	18.6 months	

Survival 5 years
Open / Laparoscopic liver resection

First authors, year	Country	No. of patients	3-year overall survival, %	5-year overall survival, %
Ito et al, 2008	USA	1,067	65	45
Blazer et al, 2008	USA	305	65	42
Adam et al, 2008	France, Netherlands	738	61	45
Zakaria et al, 2007	USA	662	55	37

First authors, year	Country	Number of patients	3-year overall survival, %	5-year overall survival, %
Nguyen et al, 2009	Multi-centre study: USA, France	109	69	50
Kazaryan et al, 2010	Norway	107	68	51
Casting et al, 2009	Two-centre study: France	60	82	64
Vibert et al, 2006	France	41	87	-
Sasaki et al, 2009	Japan	39	64	64

Open/Laparoscopic re-resections

Publication	No of patients	Perioperative mortality (%)	Survival 5 years (%)	Survival 10 years (%)
Fong et al, 1994	25	0	30 (mean)	-
Nordlinger et al, 1994	116	0,9	-	33
Fernandez-Trigo et al, 1995	170	-	34	32
Scheele et al, 1996	26	2	60	57
Adam et al, 1997	64	0	-	41
Yamamolo et al, 1997	75	0	30	31
Petrowsky et al, 2002	126	16	37	34
Shaw et al, 2006	71	1,4	74	44

First authors, year	Country	No. of pts	3-year overall survival, %	5-year overall survival, %
Shafaee et al, 2011	Tri-centre study: France, Norway, USA	55*	83	55

Is Laparoscopic Repeat Hepatectomy Feasible?
A Tri-institutional Analysis
Zahra Shafaee[1], Airazat M. Kazaryan[2], M. Marvin[3],K. Ravindra[3], Joseph F. Buell[3], Bjørn Edwin[2], Brice Gayet[1].
J Am Coll Surg. 2011 Feb;212(2):171-9.

Treatment have changed to a more aggressive approach

Multimodal vs. classic approach

"Classical" approach

- Colorectal liver metastases
- Conventional resection, Formal hepatectomy
- Repeated resection?
- Palliative chemotherapy

Multimodal treatment (more aggressive approach)

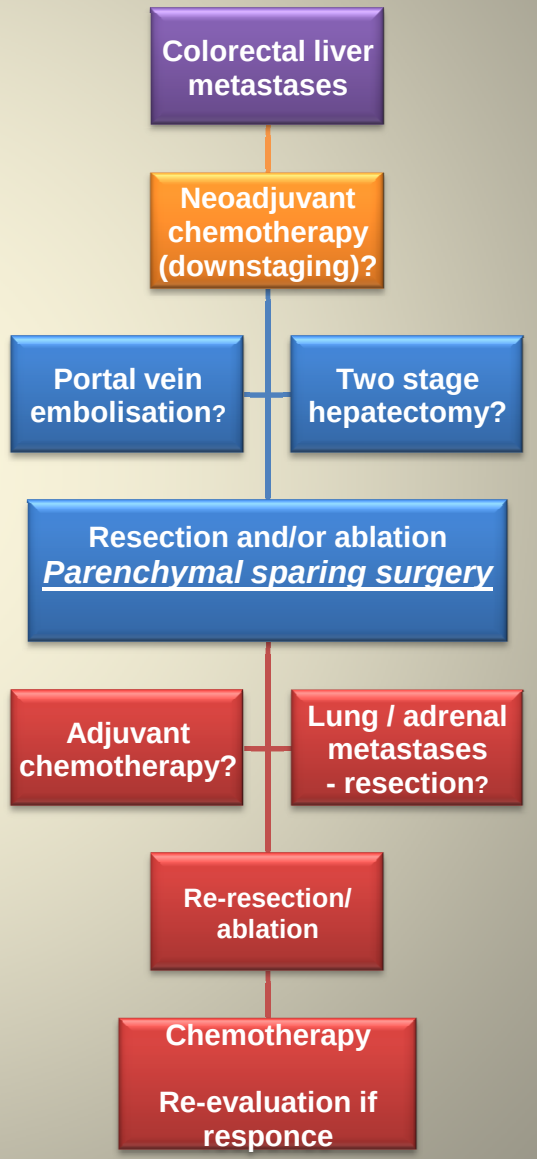

Multimodal treatment in patients with colorectal metastasis.

Change a the situation from a disease with a relatively short life expectancy, to a chronic disease with the possibility to live many years extra

(B.Edwin)---*personal opinion*

52
87
44
54
OLYMPUS

Planning both before and during the operation

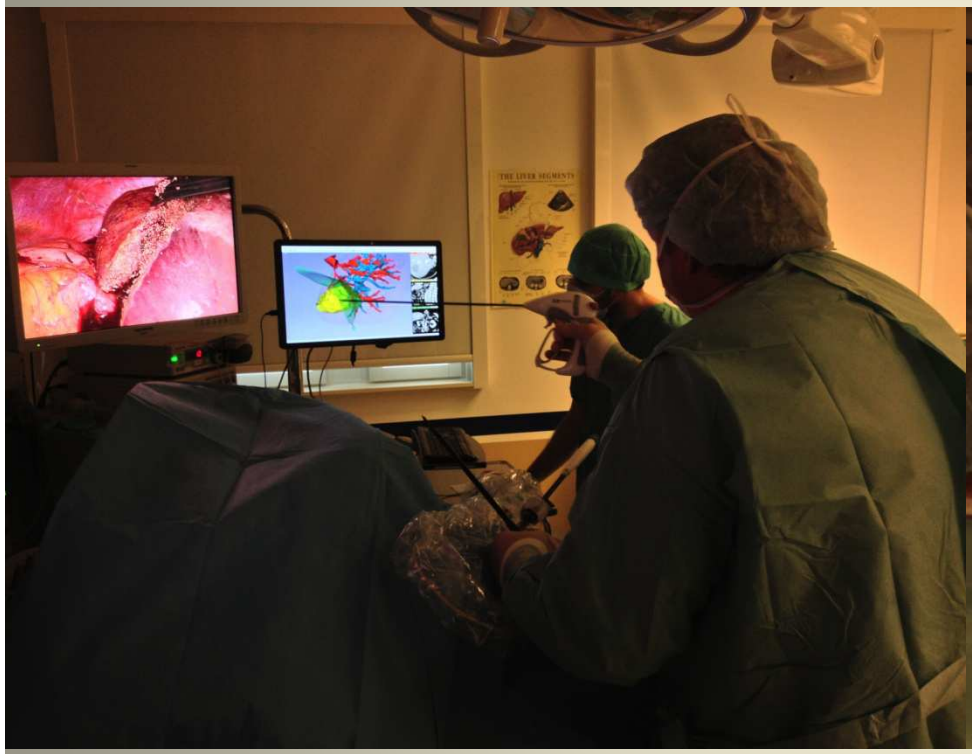

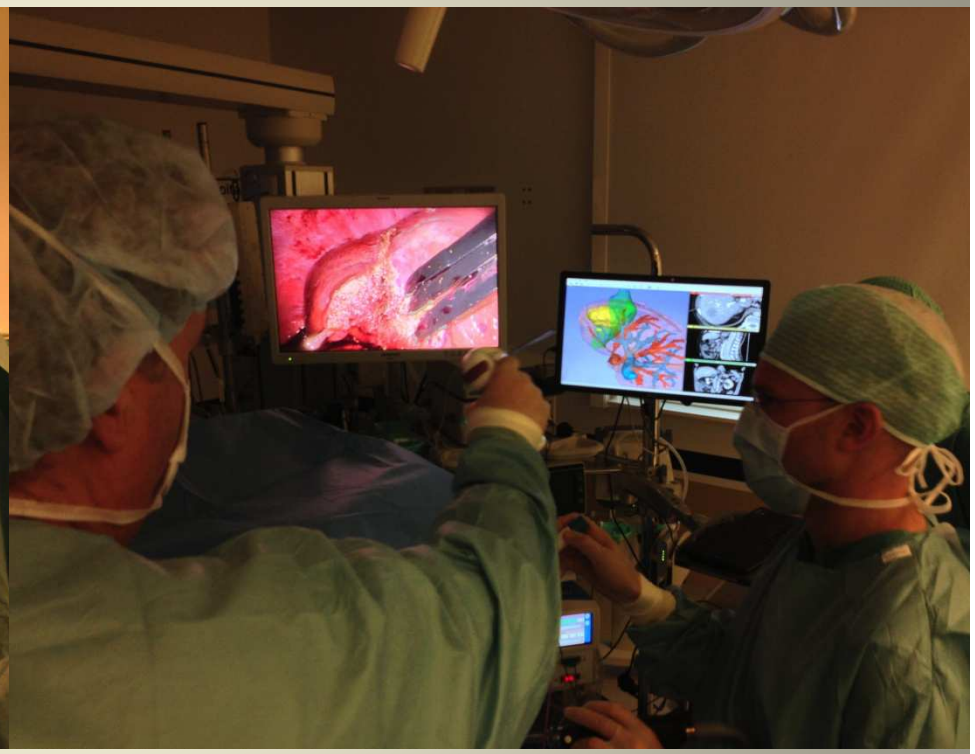

THE LIVER SEGMENTS



Parenchyma sparing techniques

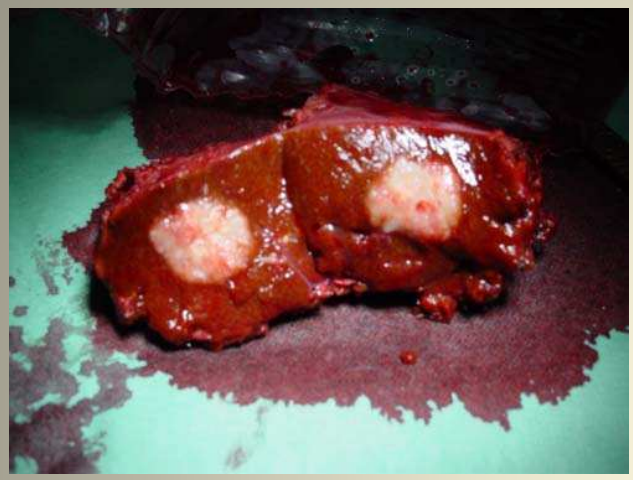

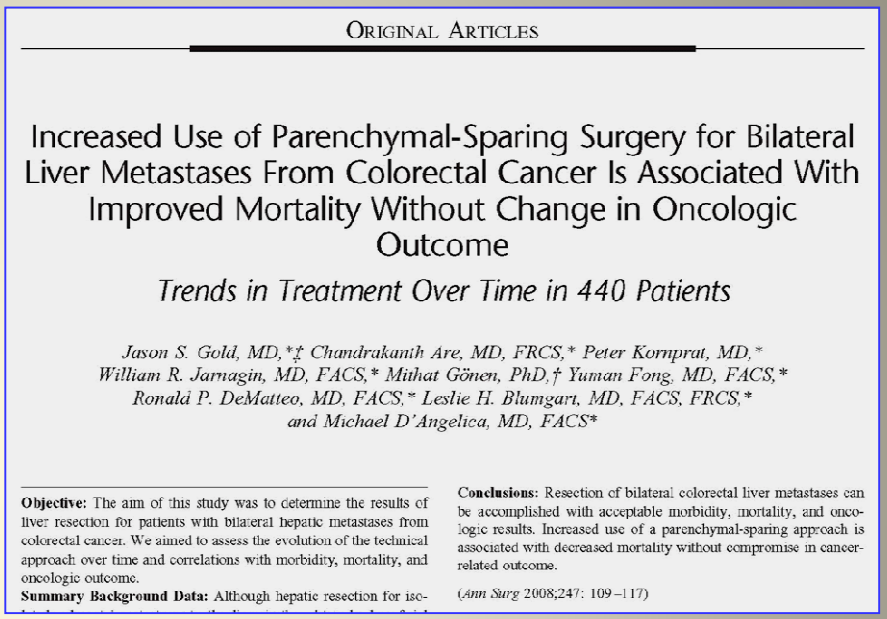

ORIGINAL ARTICLES

Increased Use of Parenchymal-Sparing Surgery for Bilateral Liver Metastases From Colorectal Cancer Is Associated With Improved Mortality Without Change in Oncologic Outcome

Trends in Treatment Over Time in 440 Patients

Jason S. Gold, MD,† Chandrakanth Are, MD, FRCS,* Peter Kornprat, MD,* William R. Jarnagin, MD, FACS,* Mithat Gönen, PhD,† Yuman Fong, MD, FACS,* Ronald P. DeMatteo, MD, FACS,* Leslie H. Blumgart, MD, FACS, FRCS,* and Michael D'Angelica, MD, FACS**

Objective: The aim of this study was to determine the results of liver resection for patients with bilateral hepatic metastases from colorectal cancer. We aimed to assess the evolution of the technical approach over time and correlations with morbidity, mortality, and oncologic outcome.

Summary Background Data: Although hepatic resection for iso-

Conclusions: Resection of bilateral colorectal liver metastases can be accomplished with acceptable morbidity, mortality, and oncologic results. Increased use of a parenchymal-sparing approach is associated with decreased mortality without compromise in cancer-related outcome.

(*Ann Surg* 2008;247: 109–117)

Decreased morbidity

Increased possibility for re-resections

Recent studies: No difference in survival between non-anatomic and anatomic resection.

No randomised studies

Parenchyma sparing technique

Factors that are important to know more about.

- Influence of resection margins on survival
- What about repeated resections?
- How recurrent metastasis occurs in the liver remnant
- Vascular anatomy --- pre and per operative planning
  - Out and inflow
  - Size of segments

Other important parameters

- Influence of Chemotherapy (neoadj./adj.) on the disease
- Tumor biology

Resection margins influence on survival and recurrence

Resection margin

2 publications 2013 and 2014: 1 mm resection margin is enough for CRLM

ORIGINAL ARTICLE

Margin status after laparoscopic resection of colorectal liver metastases: does a narrow resection margin have an influence on survival and local recurrence?

Nadya Postriganova[1,2], Airazat M. Kazaryan[1,3], Bård I. Røsok[4], Åsmund A. Fretland[1,4], Leonid Barkhatov[1] & Bjørn Edwin[1,4,5]

HPB 2013, ••, ••–••

© 2013 International

ORIGINAL ARTICLE

One-Millimeter Cancer-Free Margin Is Curative for Colorectal Liver Metastases

A Propensity Score Case-Match Approach

Zaed Z. R. Hamady, PhD, FRCS,† J. Peter A. Lodge, MD, FRCS,† Fenella K. Welsh, FRCS,* Giles J. Toogood, DM, FRCS,† Alan White, MRCS,† Timothy John, FRCS,* and Myrddin Rees, FRCS**

Annals of Surgery • Volume 259, Number 3, March 2014

Resection margin

- This supports the theory about Parenchyma Sparing Technique (PST), indirectly, in the way that a big amount of liver tissue around the tumor does not need to be resected.

What about Re-resection --- safe ?

J Gastrointest Surg. 2009 Dec;13(12):2141-51. doi: 10.1007/s11605-009-1050-0. Epub 2009 Oct 1.

Repeat curative intent liver surgery is safe and effective for recurrent colorectal liver metastasis: results from an international multi-institutional analysis.

de Jong MC, Mayo SC, Pulitano C, Lanella S, Ribero D, Strub J, Hubert C, Gigot JF, Schulick RD, Choti MA, Aldrighetti L, Mentha G, Capussotti L, Pawlik TM.

Ann Surg. 2009 Sep;250(3):440-8. doi: 10.1097/SLA.0b013e3181b4539b.

Rates and patterns of recurrence following curative intent surgery for colorectal liver metastasis: an international multi-institutional analysis of 1669 patients.

de Jong MC, Pulitano C, Ribero D, Strub J, Mentha G, Schulick RD, Choti MA, Aldrighetti L, Capussotti L, Pawlik TM.

Repeat curative intent surgery (CIS) for recurrent colorectal liver metastasis can be *performed with low morbidity and near-zero mortality*

Patients with no extra-hepatic disease are best candidates for repeat CIS.

In these patients, repeat CIS *can offer the chance of long-term survival.*

Re-resection ---open

Publication	No of patients	Perioperative mortality (%)	Survival 5 years (%)	Survival 10 years (%)
Fong et al, 1994	25	0	30 (mean)	-
Nordlinger et al, 1994	116	0,9	-	33
Fernandez-Trigo et al, 1995	170	-	34	32
Scheele et al, 1996	26	2	60	57
Adam et al, 1997	64	0	-	41
Yamamolo et al, 1997	75	0	30	31
Petrowsky et al, 2002	126	1.6N2	37	34
Shaw et al, 2006	71	1,4	74	44

N2 Obs: Perioperative mortality 1.6% (2 patients) in Petrowsky study
Norstein; 30/09/2014

Re-resection --- Laparoscopic

Result-CRLM

First authors, year	Country	No. of pts	3-year overall survival, %	5-year overall survival, %
Shafaee et al, 2011	Tri-centre study: France, Norway, USA	55*	83	55

Is Laparoscopic Repeat Hepatectomy Feasible?
A Tri-institutional Analysis
Zahra Shafaee[1], Airazat M. Kazaryan[2],
M. Marvin[3],K. Ravindra[3], Joseph F. Buell[3],
Bjørn Edwin[2], Brice Gayet[1].
J Am Coll Surg. 2011 Feb;212(2):171-9.

- **Laparoscopic repeat hepatic resections can be performed safely and with good results, *particularly in patients with earlier laparoscopic resections.***

Why laparoscopy

Theoretical advantages

J Hepatobiliary Pancreat Sci. 2014 Oct;21(10):723-31. doi: 10.1002/jhbp.139. Epub 2014 Aug 5.

Laparoscopic hepatectomy is theoretically better than open hepatectomy: preparing for the 2nd International Consensus Conference on Laparoscopic Liver Resection.

Wakabayashi G, Cherqui D, Geller DA, Han HS, Kaneko H, Buell JF.

Six years have passed since the first International Consensus Conference on Laparoscopic Liver Resection was held. This comparatively new surgical technique has evolved since then and is rapidly being adopted worldwide. We compared the theoretical differences between open and laparoscopic liver resection, using right hepatectomy as an example. We also searched the Cochrane Library using the keyword "laparoscopic liver resection." The papers retrieved through the search were reviewed, categorized, and applied to the clinical questions that will be discussed at the 2nd Consensus Conference. The laparoscopic hepatectomy procedure is more difficult to master than the open hepatectomy procedure because of the movement restrictions imposed upon us when we operate from outside the body cavity. However, good visibility of the operative field around the liver, which is located beneath the costal arch, and the magnifying provide for neat transection of the hepatic parenchyma. Another theoretical advantage is that pneumoperitoneum pressure reduces hemorrhage from the hepatic vein. The literature search turned up 67 papers, 23 of which we excluded, leaving only 44. Two randomized controlled trials (RCTs) are underway, but their results are yet to be published. Most of the studies (n = 15) concerned short-term results, with some addressing long-term results (n = 7), cost (n = 6), energy devices (n = 4), and so on. **Laparoscopic hepatectomy is theoretically superior to open hepatectomy in terms of good visibility of the operative field due to the magnifying effect and reduced hemorrhage from the hepatic vein due to pneumoperitoneum pressure. However, there is as yet no evidence from previous studies to back this up in terms of short-term and long-term results.** The 2nd International Consensus Conference on Laparoscopic Liver Resection will arrive at a consensus on the basis of the best available evidence, with video presentations focusing on surgical techniques and the publication of guidelines for the standardization of procedures based on the experience of experts.

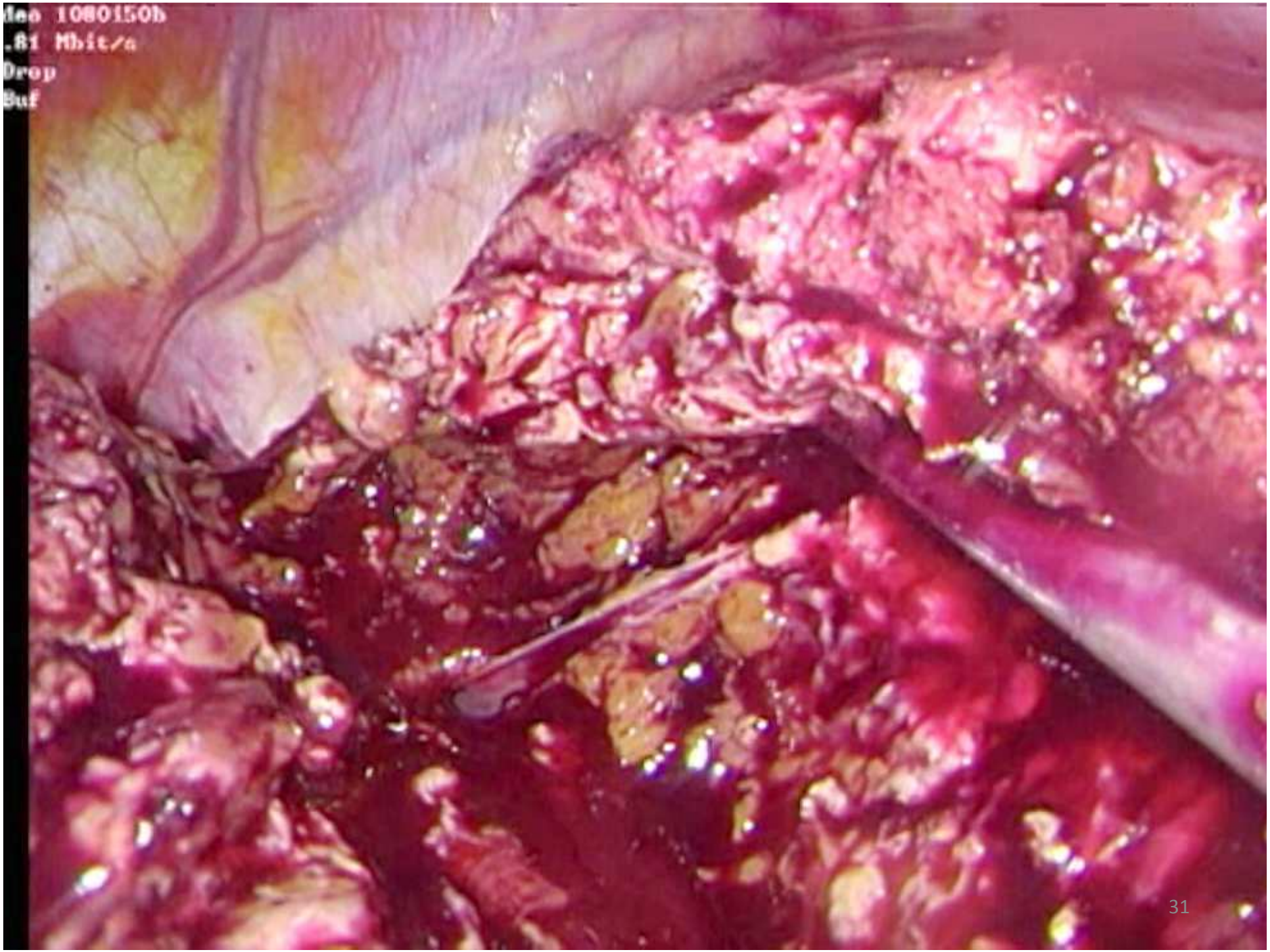
Mbit/s
Drop
Buf

Why laparoscopy ?

- Less adhesions, easier to perform repeated resections
- Laurent et al, J Hepatobiliary pancreat surg 2009: *Laparoscopic liver resection facilitates salvage liver transplantation for hepatocellular carcinoma.*
- *Personal experience*

How metastasis occurs in the liver remnant

Aim: To determine if recurrent liver metastases recur in the same liver lobe as initial metastases, or in the contralateral lobe.

85 patients were found eligible for the study:

- only patients with **repeated metastases** after **primary liver surgery for colorectal metastases** were included

Patients divided into three groups:

Group I – initial metastases in the left lobe (n= 25)
Group II – initial metastases in the right lobe (n= 40)
Group III – initial metastases in both lobes (n= 20)

So what …..

More then 50% of recurrent liver metastases

appear in the contralateral lobe or bi-lobar

This means ……

After formal resections compared with parenchyma sparing technique, the patients have less chance of further surgical treatment

Parenchyma sparing technique
Pre and per operative planning --- 3D map
Vascular Anatomy – In- and outflow, size of segments
Important knowledge

Case report:
Major resection or Parenchyma-sparing:

- Patient E. – female 48 years old;
- Sigmoideum resection in Jan. 2012, Dukes D cancer
- Syncron liver metastasis in S7, 17 mm

CT-scan, initial met in S7

Op. 3 month after sigm. res.

Local resection S 7 --- specimen 70*50*20 mm

Tumor 25 mm free resection margin

CT-scan – 3 month after operation

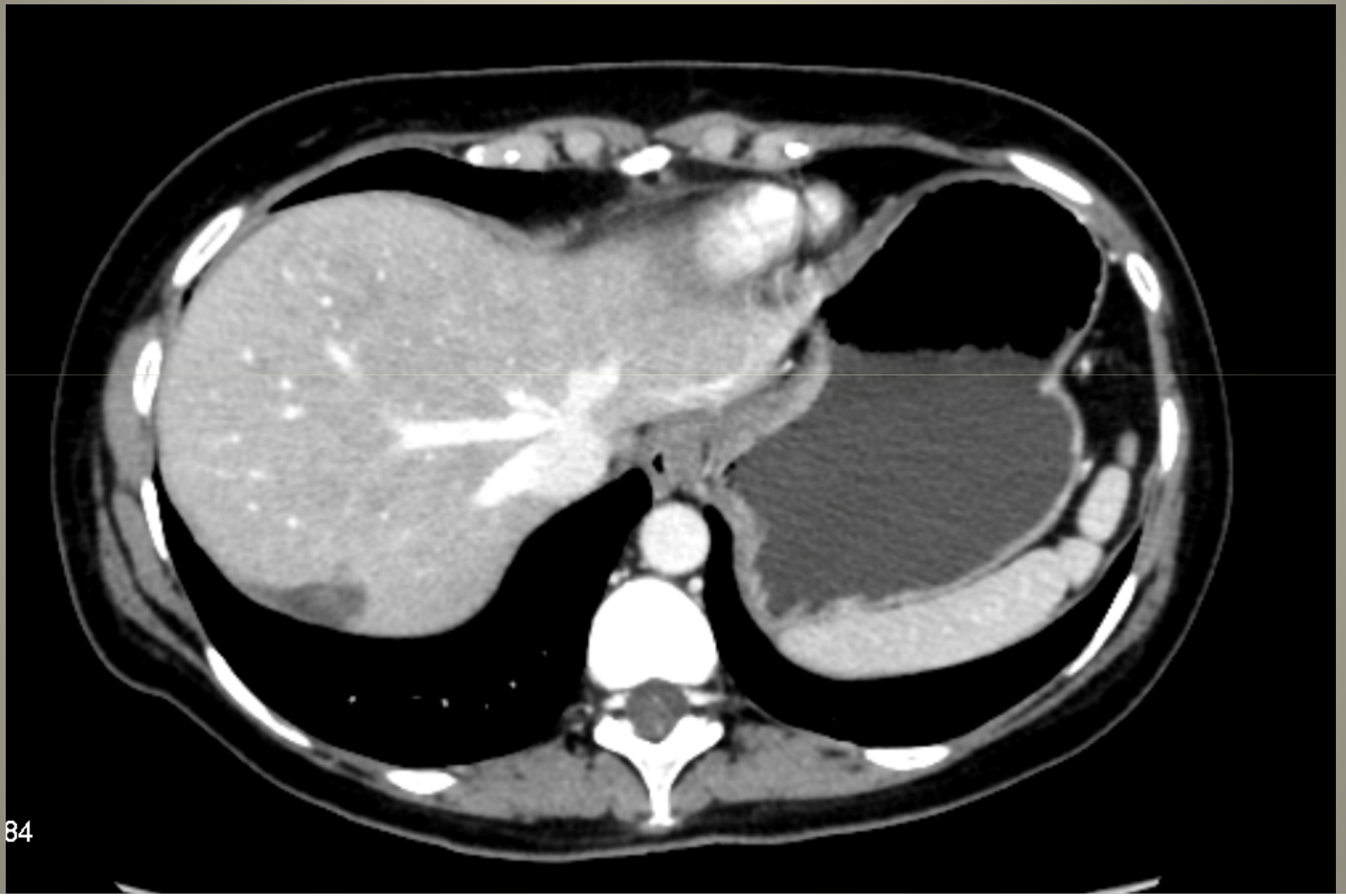

Recurrence 14 month after liver resection, seg 6/7

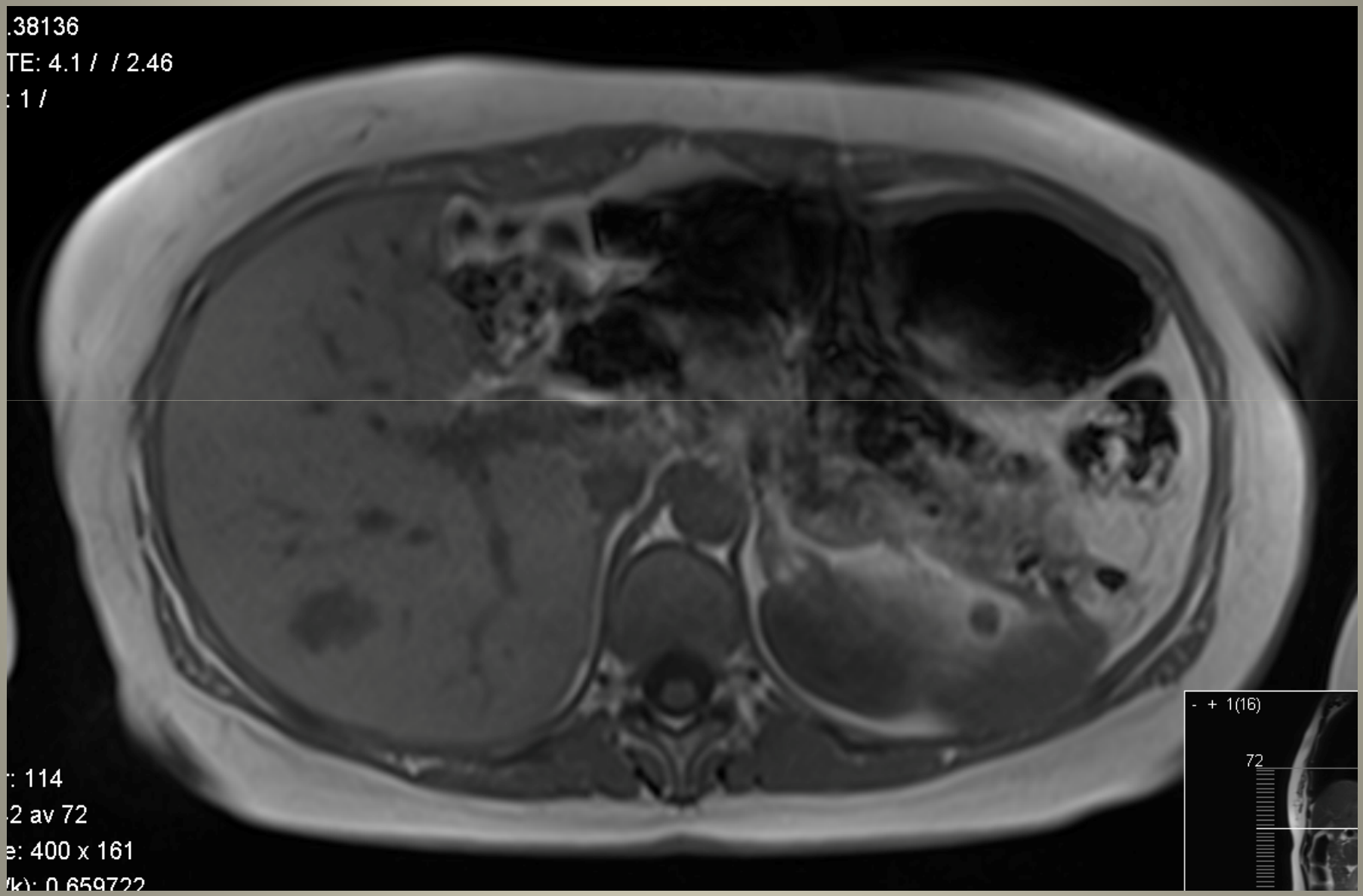

- Op.14 month after 1st liver resection
- Local resection of segment 6/7
- Tumor – 25 mm
- Specimen 110*80*40 mm, 117 g
- Free resection margin

After 6 month recurrence– S5, S7, S2

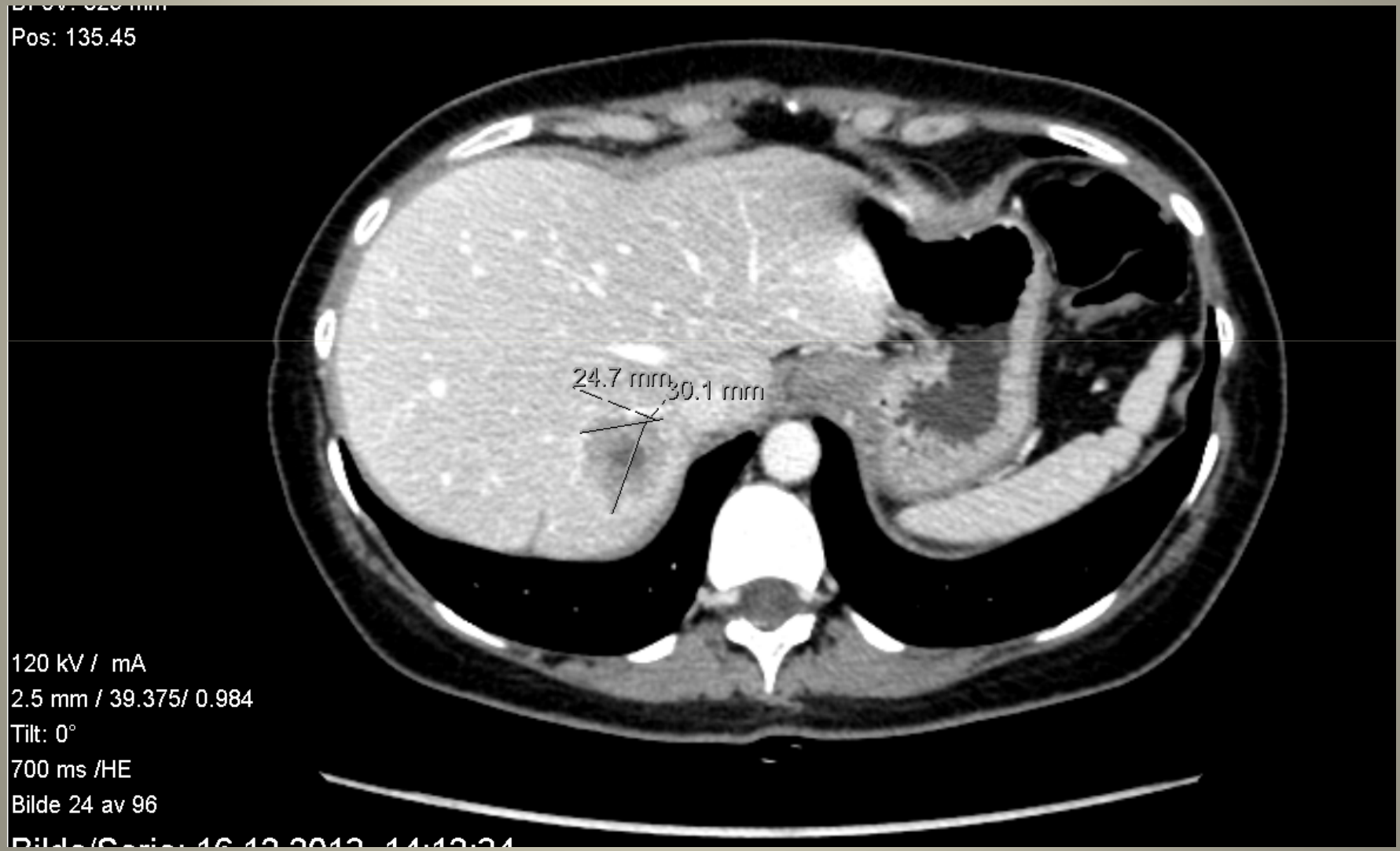

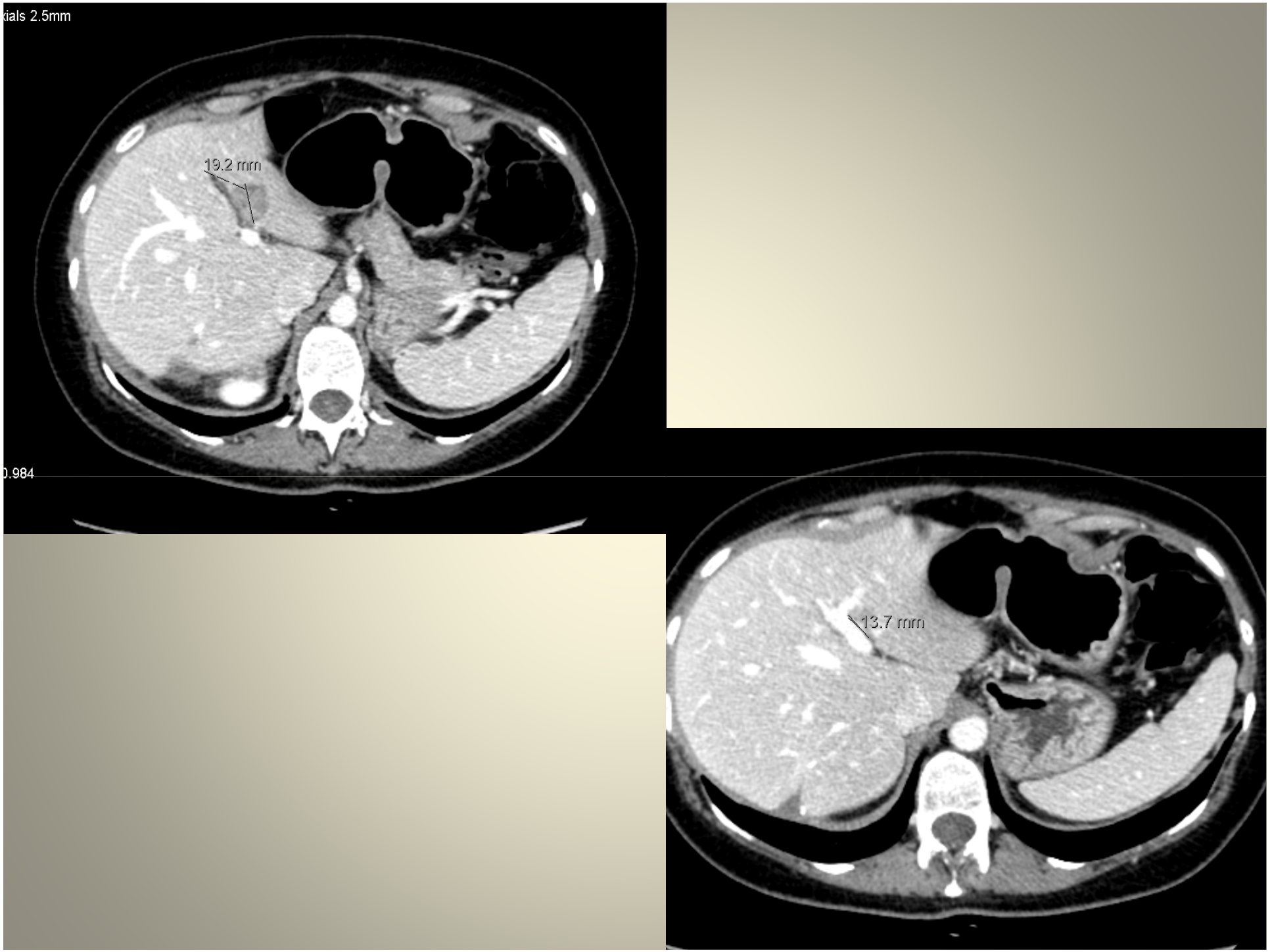
ials 2.5mm
19.2 mm
0.984
13.7 mm

- Operated 6 month after 2nd liver resection and 2 years after colon resection
- local resection S7

  specimen 60*55*20 mm, 64 g, tumor 28 mm
- local resection S5

  specimen 35*28*18, 12 g, tumor 14 mm
- left lateral resection, extended to seg 4

  specimen 100*70*25, 127 g, tumor 22 mm

- free margins

CT-scan 1 day after operation

What is next step?

Oslo CoMet study

OSlo Laparoscopic vs. Open resection of COlorectal METastases study.

- Clinicaltrials.gov id: NCT01516710
- Regional ethical approval after dedicated meeting with committee

  - "Is randomization really necessary?"
  - "Yes, and it's now or never"

The Comet-story so far

- From Feb 15th 2012 to Oct 1st 2014:
  - 186 Patients included
  - Most patients accept
    - Patients demand laparotomy (n=3)

Immunology: There is a difference in the inflammatory response!

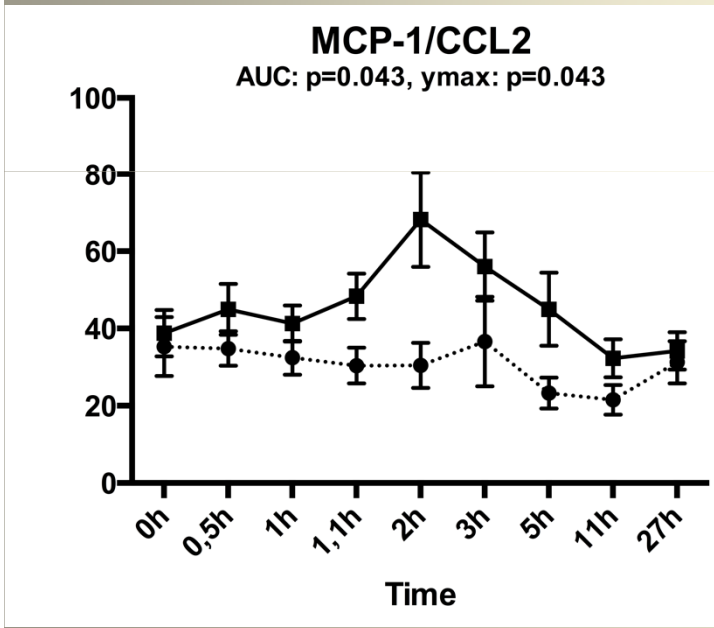

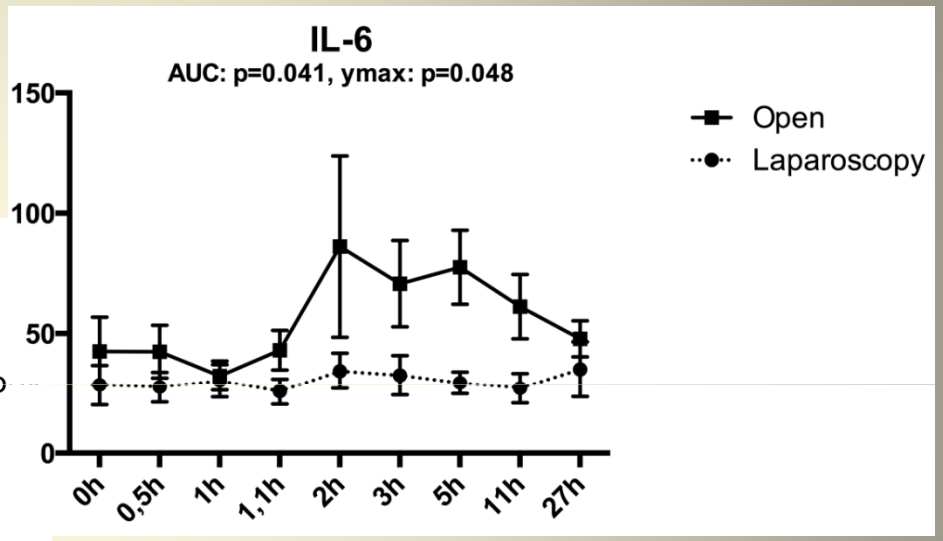

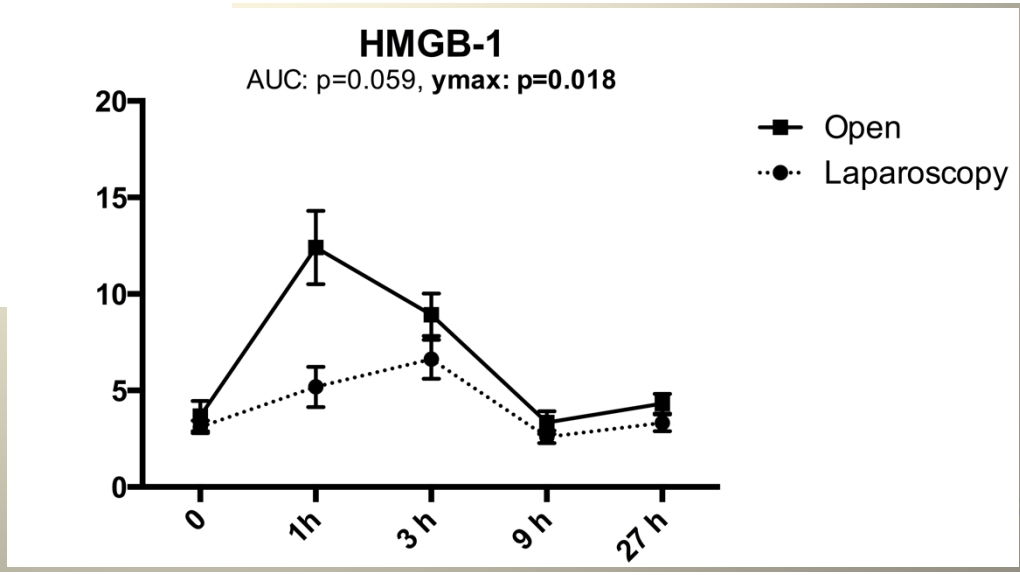

There is a difference in Quality of Life!

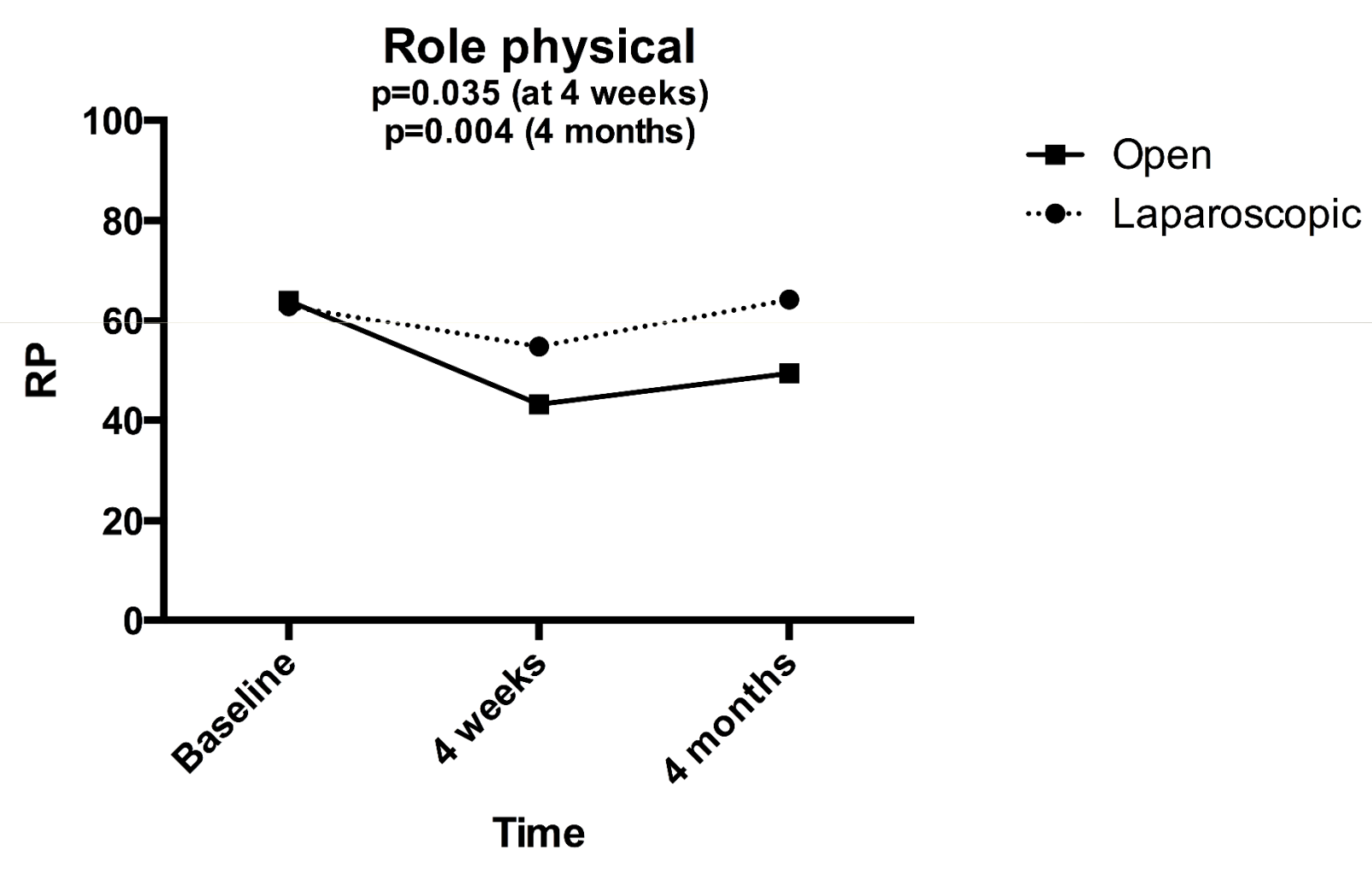

Why laparoscopy?

- ”Better” for the patient
  - Less pain, faster back to activity, cosmetic
- Easier re-resections/transplant
- Less immune response
- Better QoL
- *But we need randomized data!*

What to discuss?

- In our opinion, the discussion is now
  - Parenchyma sparing resections
  - How to avoid formal resections
  - How to do them laparoscopically when needed



It is not the strongest, nor the most intelligent who survive, but those most responsive to change.

Charles Darwin (1809-1888)

Thank you very much for your attention!

Formal right hemi hepatectomy?
Vascular anatomy

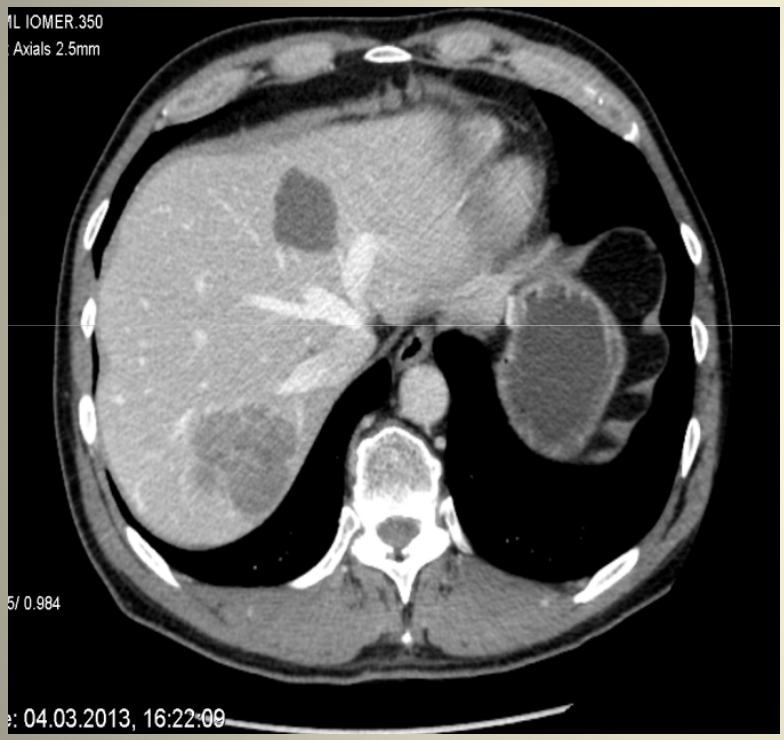

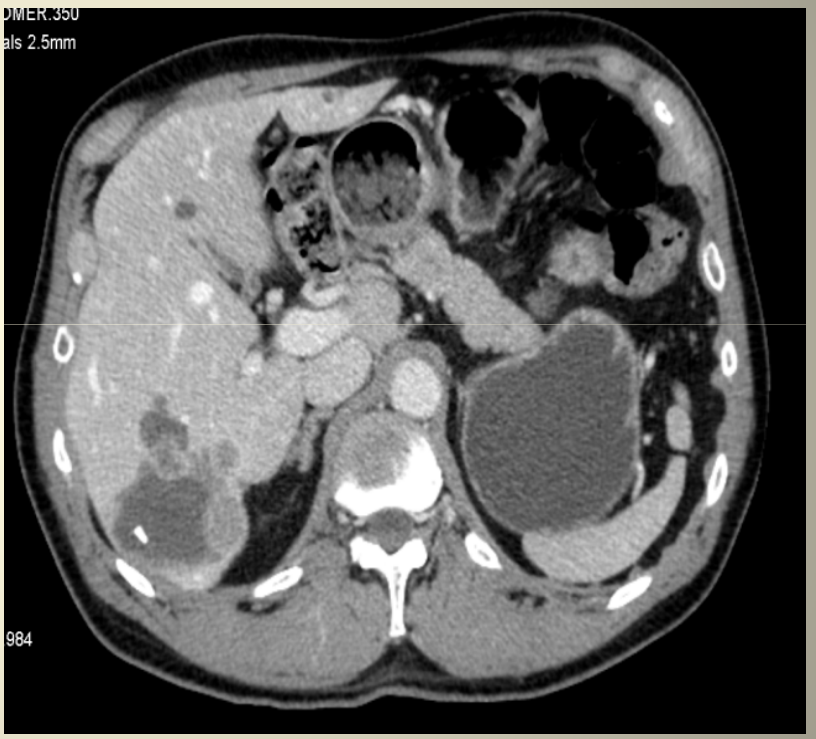

NO!

Segm.II and III too small

Can we remove the tumor? N4

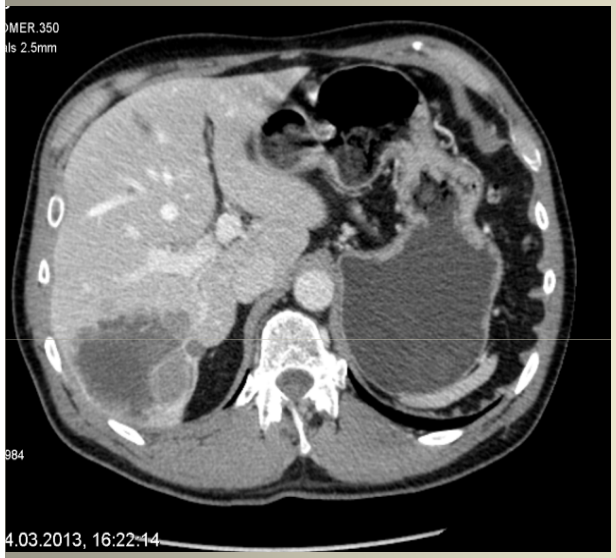

Vascular anatomy --- Important !!!

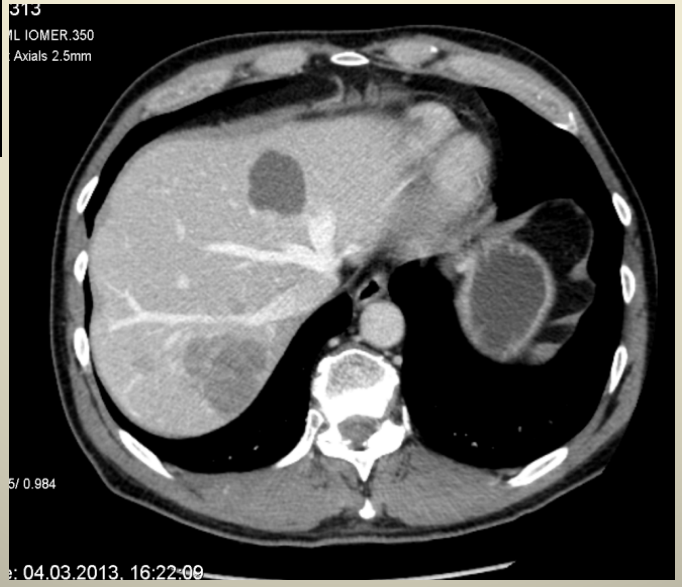

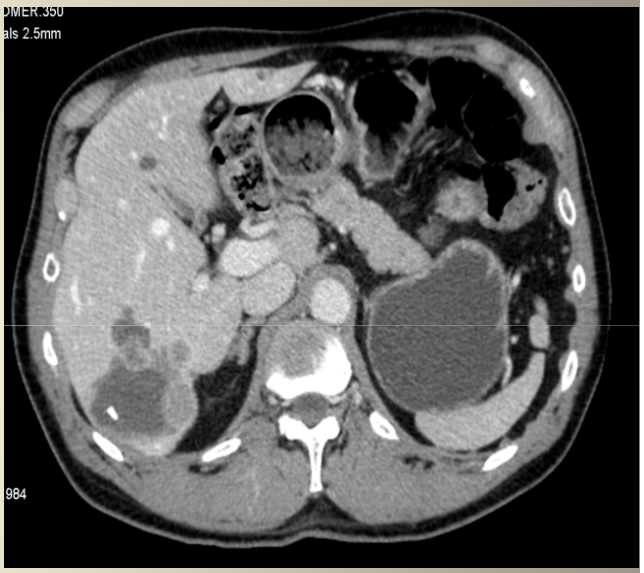

N4 "What about segment 4?
Norstein; 30/09/2014

YES!

Segm. V and VIII drains to the MHV, segm. VI and VII can be removed with the tumor and the RHV
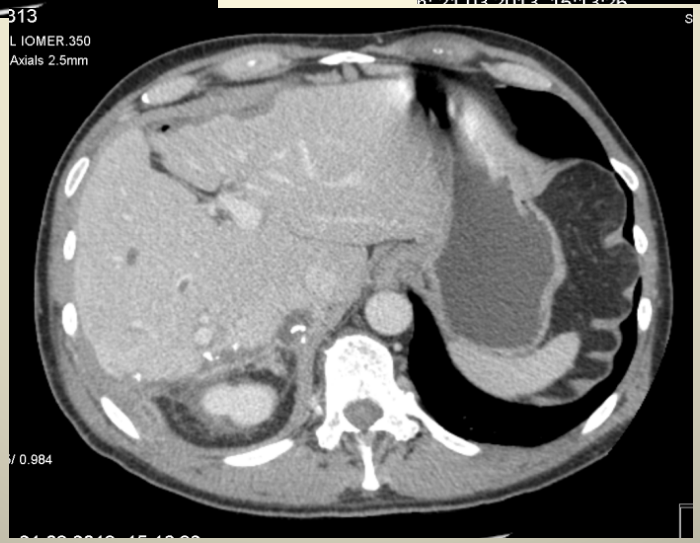
Post operative result.